Case Report

Use of PCSO-524® (Antinol®) in a Pomeranian Dog with Degenerative Mitral Valve Disease (DMVD) and Cardiac Tumor of the Left Atrium

Kanok Bamrungsri, DVM
Changwattana Animal Hospital

Antinol® (PCSO-524®)
Case Study Contest 2020

Use of PCSO-524® (Antinol®) in a Pomeranian Dog with Degenerative Mitral Valve Disease (DMVD) and Cardiac Tumor of the Left Atrium

Kanok Bamrungsri, DVM, Changwattana Animal Hospital

Abstract

A 10-year old Pomeranian dog with degenerative mitral valve disease (DMVD) and cardiac tumor of the left atrium was treated with **pimobendan, ramipril,** and **furosemide** in conjunction with **PCSO-524® (Antinol®)** as supplemental therapy.

After the treatment, the dog showed improved ability to conduct various activities, increased appetite and ingestion, weight gain and disappearance of paroxysmal ventricular premature contraction (VPC).

The C-reactive protein (CRP), which is an inflammatory marker in dogs, also decreased to normal level within 21 days of PCSO-524® (Antinol®) supplementation.

Keywords: PCSO-524® (Antinol®), Degenerative Mitral Valve Disease (DMVD), cardiac tumor

Introduction

Degenerative Mitral Valve Disease (DMVD) is a common cardiovascular disease found in dogs that approximately 30% of dogs older than 10 years are affected by the disease (Oyama A., 2012).

Symptoms of the disease include degeneration and thickening of mitral valve which causes mitral value insufficiency (Suh H., et al., 2012). The disease is characterized by systolic murmur heard at the left sternal border which indicates degenerative mitral valve disease (DMVD) and mitral regurgitation (MR).

Degenerative Mitral Valve Disease (DMVD) is frequently found in **small breed dogs** and some specific breed dogs with high risk, for example, Cavalier King Charles Spaniels dogs that develop degeneration of mitral valve for the entire life.

When the condition of degenerative mitral valve disease (DMVD) is worse, the degree of mitral regurgitation (MR) increases (Oyama A., 2012) and leads to congestive heart failure and pulmonary edema. If the dilation of the left atrium can no longer compensate for the dynamics of blood flow, mitral regurgitation will cause volume overload and death may occur due to cardiac failure in dogs (Suh H. et al., 2012).

Cardiac tumor is often identified by chance in dogs and cats. The tumors that are frequently found include hemangiosarcoma (HSA), aortic body tumors (chemodectoma and paraganglioma) lymphoma and ectopic thyroid carcinoma. The degree of symptoms ranges from mild to severe depending on type of tumor, disturbances in the cardiovascular system, location of the hemorrhage, and pericardial effusion.

Treatment for cardiac tumor is symptomatic and aimed for **control of bleeding** caused by the tumor, arrhythmia, and other complications (Treggiari E. et al., 2017).

Primary cardiac tumor originates from the heart and the secondary tumor is caused by metastasis to the heart (Aupperle et al, 2007). Ultrasonography imaging often identifies cardiac tumor but to differentiate the type of tumor, pathological examination at post mortem is necessary (Treggiari E. et al., 2017).

The tool with highest potential for ante-mortem diagnosis of cardiac tumor is **echocardiography**, which processes information of tumor location and tumor characteristics, such as echo texture and invasiveness, to develop a diagnosis result.

A retrospective study conducted by University of Tennessee and John and Ann Tickle Small Animal Hospital during 2006-2012 in 24 dogs compared diagnosis results for type of tumor at the heart base between ultrasonography and pathological examination. The ultrasonography was able to correctly identify chemodectoma, ectopic thyroid carcinoma and lymphoma in 7 out of 9 dogs that was diagnosed with the diseases by **pathological examination.**

The two diagnosis tools also showed agreement for diagnosis of **hemangiosarcoma**, which is a tumor of the right atrium, in 4 out of 8 dogs. The ultrasonography also detected pericardial effusion in 10 out of 24 dogs and ECG abnormalities in 8 out of 24 dogs. Survival time of dogs affected with the disease is between less than 1 day to greater than 150 days.

Diagnosis of tumor type by locating the tumor using **echocardiogram** is moderately accurate and additional examination tool is essential, such as analysis of **cardiac troponin** and **pericardial fluid, fine-needle aspiration, serum T4 concentration, cross-sectional imaging,** and **thoracoscopy** or thoracotomy. Tumor types most often identified by echocardiographic examination are HSA, CD, ETC, and LSA (Rajagopalan V. et al., 2013). Low level of eicosapentaenoic acid (EPA) and docosahexaenoic acid (DHA), components of omega-3 polyunsaturated fatty acids, are found in cell membrane and can increase by supplementation of diet that promotes cardiac function and appetite, and reduces inflammation and cardiac arrhythmia (Freeman, 2013).

Case History

A 10 years old, intact, male Pomeranian dog weighed 2.1 kilograms had gradually lost body weight from 2.85 to 2.1 kilograms during the past 2 years.

The dog showed signs of depression, fatigue, lethargy, loss of appetite, occasionally cyanotic mucous membrane, paresis of hind legs, general and rat tail alopecia, and pigmented skin. The dog was fed with Royal Canin® adult dogs formula.

Diagnostic plan and diagnosis

Physical examination found 99 °F body temperature, 2/5 body condition score, paresis of hind legs, restlessness, occasional dyspnea, cyanotic mucous membrane during the examination but normal at rest, CRT less than 2 seconds, 140 beats per min heart rate, murmur level 3, 124 and 90 mmHg for systolic and diastolic pressure, respectively, general and rat tail alopecia, and pigmented skin.

Hematological and biochemical test results

Hematological tests showed results within normal ranges (Table 1).
Blood chemical tests found that
C-Reactive Protein (CRP) was 51.7 mg/L, which was higher than normal (Table 2),
thyroid hormone was normal (1.4 mcg/dl) and blood glucose was 90 mg/dl.

Radiographic examination

X-ray images revealed normal heart size with vertebral heart score (VSH) 10.1 (Figure 1) and electrocardiogram examination found paroxysmal ventricular premature complex (VPC) of the heart (Figure 3).

Degenerative Mitral Valve Disease (DMVD) with severe Mitral Regurgitation and **left atrial enlargement** was identified (Table 3). A mass was found at left atrium near the heart base and heart base tumor was diagnosed (Figure 5).

Treatment outcome and Follow-up

The dog received oxygen therapy for 24 hours and ramipril 1.25 mg 0.5 tablet sid, pimobendan 1.25 mg 0.5 tablet bid, furosemide 40 mg 0.125 tablet bid were prescribed.
After 7 days of treatment, PCSO-524® (Antinol®) 1 capsule bid was added to the program.

Improvement of clinical signs including **normal mucous membrane, CRT** less than 2 seconds, and **absence of dyspnea** were observed after 7 days of the treatment but lethargy and loss of appetite still remained. When PCSO-524® (Antinol®) was given to the dog after 7 days of the treatment, the dog apparently gained alertness and engaged in various activities with improvement of motility balance and no dyspnea. Prolonged period of walking and running was observed at 30 and 60 days, respectively, after PCSO-524® (Antinol®) was administered. The dog had regained appetite and the body weight increased from 2.1 to 2.55 kilograms within 6 months.

Hematological examination before and after the administration of PCSO-524® (Antinol®) showed no significant difference (Table 1).

Table 1. Hematological test results before and after the administration of PCSO-524® (Antinol®)

CBC	unit	Normal values	Day -7*	Day 0**	Day 7	Day 14	Day 21	Day 30	Day 45	Day 60	Day 90	Day 120	Day 150	Day 180
RBC	x106/µl	5.5-8.5	6.6	6.7	7.7	6.9	6.8	6.3	7.7	7	7.4	7.7	7.2	6.2
Hemoglobin	g/dl	12.0-18.0	15.6	15.8	18.3	16.3	15.7	13.8	16.2	16.9	16.1	17.9	16.7	14.3
Haematocrit	%	37.0-55.0	46	43	55	44	48	42	48	45	47	51	47	43
WBC	Cell/ mm3	6.0-17	8,800	11,900	11,800	6,000	10,100	7,200	7,100	9,800	9,100	12,800	8,600	6,300
Neutrophils	%	60-77	70	70	76	77	77	70	76	85	83	81	63	66
Bands	%	0-3	0	0	0	0	0	0	0	0	0	0	0	0
Eosinophils	%	2.0-10.0	1	6	1	3	5	6	6	0	4	2	6	5
Lymphocytes	%	12.0-30.0	26	22	20	17	16	23	15	13	10	15	29	28
Monocytes	%	3.0-10.0	3	2	3	3	2	1	3	2	3	2	2	1
Platelet	103/µl	200-500	268,000	204,000	314,000	246,000	354,000	334,000	324,000	462,000	226,000	212,000	373,000	584,000

Biochemical tests performed on day 21 after PCSO-524® (Antinol®) was started showed that **C-reactive protein (CRP)** returned to normal value and remained normal until 6 months after the treatment (Table 2).

Table 2. Blood chemical test results before and after the administration of PCSO-524® (Antinol®)

Blood Chemistry	unit	Normal values	Day -7*	Day 0**	Day 7	Day 14	Day 21	Day 30	Day 45	Day 60	Day 90	Day 120	Day 150	Day 180
ALT(SGPT)	Units	10.0-118.0	100	98	78	43	65	102	112	65	92	86	96	75
Alkaline Phosphatase	pIU/Ls	20.0-150.0	102	87	116	99	78	65	98	90	110	135	85	89
BUN	mg%	7.0-25.0	18	12	14	14	15	13	14	13	13	15	17	12
Creatinine	mg%	0.3-1.5	1.1	1.3	0.9	1.3	1.4	1.3	1.3	1.2	1.4	1.3	1	1.3
CRP	mg/L	<20	51.7	63.2	39.5	22.4	<10	<10	<10	<10	<10	<10	<10	<10

*Day-7: Time period when DMVD and cardiac tumor were treated with pimobendan, ramipril and furosemide without PCSO-524® (Antinol®) supplement.
**Day0: The day when PCSO-524® (Antinol®) was started.
D7-D180: Day7 to Day180 after the treatment with PCSO-524® (Antinol®) supplement.

Radiographic and Echocardiogram examination results

X-ray images of thoracic cavity showed that Vertebral Heart Score (VSH) was 10.1 prior to the treatment (Figure 1) and back to normal range, 10.6, after the treatment (Figure 2).

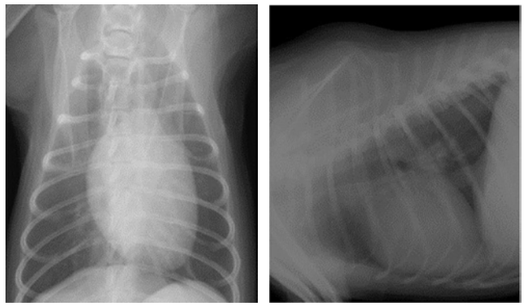

Figure 1. X-ray image of thoracic cavity of a 10 years old male Pomeranian dog showed that Vertebral Heart Score (VSH) was 10.1 prior to the treatment

Figure 3. Echocardiogram (ECG) prior to the treatment

Echocardiogram prior to the treatment found **paroxysmal ventricular premature contraction (VPC)** (Figure 3) and **respiratory sinus arrhythmia** was found without ventricular premature contraction (VPC) after the treatment (Figure 4).

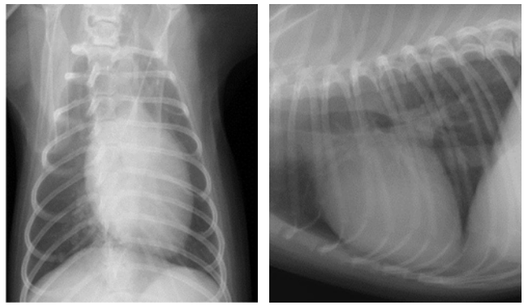

Figure 2. X-ray image of thoracic cavity of a 10 years old male Pomeranian dog showed that Vertebral Heart Score (VSH) was 10.6 after the treatment

Figure 4. Echocardiogram (ECG) after the treatment

The echocardiogram examination revealed Degenerative Mitral Valve Disease (DMVD) with **severe Mitral Regurgitation (MR)** and **left atrial enlargement** (Table 3) and a mass in the left atrium at the heart base. The dog was diagnosed with **heart base tumor** both prior to the treatment (Figure 5) and after the treatment (Figure 6).

Table 3. Results of echocardiogram examination prior to and after the treatment

Echocardiogram	Before treatment	After treatment
1. Degenerative Mitral Valve Disease (DMVD)		
2. Mitral Regurgitation (MR)	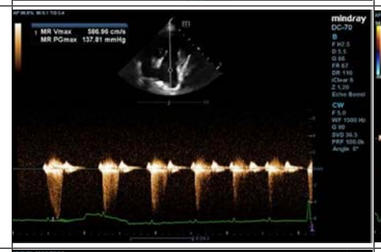	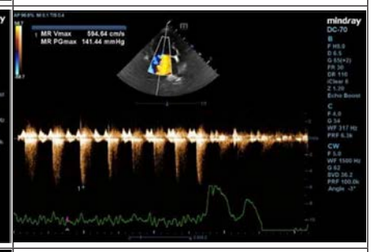
3. Color flow	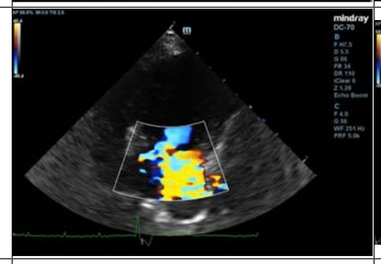	
4. LA/Ao ratio	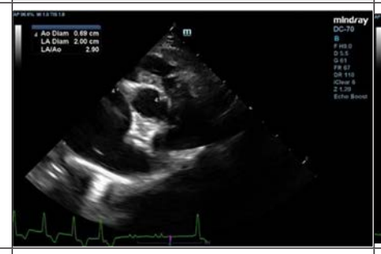	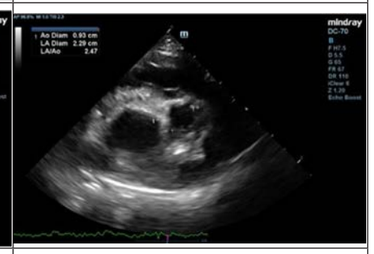
5. M-mode Echocardiography	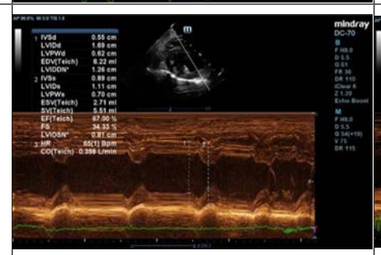	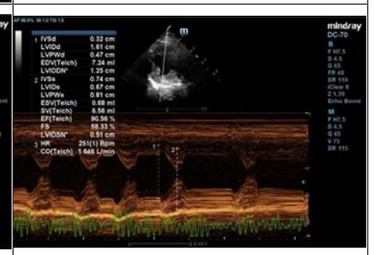

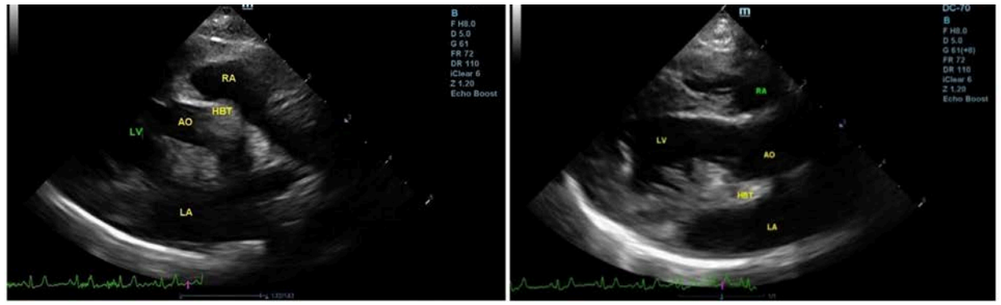

Figure 5. Results of echocardiogram examination prior to the treatment showed cardiac mass in the left atrium at the heart base which led to diagnosis of heart base tumor

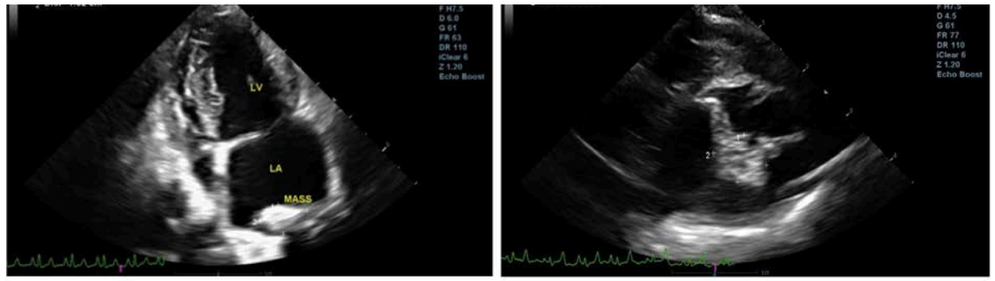

Figure 6. Results of echocardiogram examination after the treatment showed cardiac mass in the left atrium at the heart base which led to diagnosis of heart base tumor

Discussion

Within 6 months of the cardiac tumor treatment with PCSO-524® (Antinol®), the dog showed signs of recovery which included becoming more energetic, lack of dyspnea, resuming normal activities, improved motility balance, stable walking and running, increased appetite, and increased body weight from 2.1 to 2.55 kilograms.

Supplementation of Omega-3 is effective in humans with **congestive heart failure** (CHF) and also effective against **cardiac arrhythmia in dogs.**

Anti-inflammatory action of omega-3 is the effect of decreased inflammatory cytokine in cardiovascular system resulting in increased appetite in dogs with cardiac cachexia. The recommended dosage of EPA and DHA in dogs is 40 and 25 mg/kg, respectively (Cunningham and Hall, 2011).

PCSO-524® (Antinol®) is extracted from New Zealand Green Lipped mussels (Perna Caniculus) and additionally added with olive oil and vitamin E.

It contains **sterol esters, sterols, polar lipids, triglycerides and free fatty acid; EPA and DHA**, which inhibit the action of proinflammatory leukotriene (LT) B4 in human monocytes and decrease thromboxane B2, prostaglandin (PG) E2 and interleukin (IL) 1β.

The mechanism of action is similar to that of **omega-3 PUFA** (Mickleborough, 2013). The anti-inflammatory effect is demonstrated for both prevention and treatment of the disease. Other additional effects include **gastroprotective, antihistamine, antioxidant, anticytokines and antiarthritis effects** (Coulson et al., 2015).

The study found decrease of C-reactive protein (CRP) on day 21 after the treatment with PCSO-524® (Antinol®). C-reactive protein (CRP) is an acute phase protein that is an essential inflammatory marker synthetized in liver of dogs and can rapidly increase during an acute inflammation and decrease when the cause of inflammation is removed.

PCSO-524® (Antinol®) is a diet supplement that mainly contains **omega-3** polyunsaturated fatty acid, such as **eicosapentaenoic (EPA) and docosahexaenoic (DHA),** which are known for **cardio protective effect, anti-inflammatory effect and immunomodulatory activity.** The amount of omega-3 polyunsaturated fatty acids contained in PCSO-524® (Antinol®) is more than that found in fish oil (Jamikorn and Yibchok-anun, 2014).

The echocardiogram examination revealed that paroxysmal ventricular premature contraction (VPC) disappeared on day 21 after the treatment with PCSO-524® (Antinol®). **Paroxysmal ventricular premature contraction (VPC)** is caused by electrical pulse from ventricle that interacts with the normal cardiac pulse. It can occur individually, in double, triple or more pulses, sometimes results in paroxysmal or tachycardia that lasts for more than 15-30 seconds.

The cause may be associated or not associated with the heart, for example, ventricular hypertrophy (concentric or eccentric hypertrophy), hypoxemia, hypovolemia, hypotension, acid-base imbalance, electrolyte disturbance, trauma, cytokines, some medications such as digitalis, barbiturates, and antiarrhythmic drugs, myocardial ischemia, pain, gastric dilation-volvulus, and shock. The true cause of arrhythmia should be identified in order to achieve treatment success (Schwartz D. et al., 2009).

VPC can result in reduction of cardiac output, atrial blood pressure, vascular flow, and hypotension. Ventricular arrhythmia may lead to fluctuation of electrical pulse and death from ventricular fibrillation (Schwartz D. et al., 2009).

Conclusion

Use of PCSO-524® (Antinol®) in a dog with degenerative mitral valve degeneration and cardiac tumor in this study was successful for improvement of life quality, resumption of activities, increased appetite and body weight as a result of the effect of **omega-3 polyunsaturated fatty acids**.

The eicosapentaenoic (EPA), docosahexaenoic (DHA), omega-3 polyunsaturated fatty acid, are known to have cardio protective effect, anti-inflammatory effect, and immunomodulatory activity, particularly by inhibition of the action of C-reactive protein (CRP), which is an inflammatory marker in dogs.

It also eliminated paroxysmal ventricular premature contraction (VPC) in this case, which may due to the action of polyunsaturated fatty acids since there was a report on successful use of polyunsaturated fatty acids to reduce degree of cardiac arrhythmia (Freeman, 2013). The effect of omega-3 fatty acid for prevention of ischemic-induce ventricular fibrillation was also demonstrated in experimental dogs (Billman G. et al., 1999).

Cardiac cachexia is a condition of body mass loss due to irregularity of cardiac function. The condition is common in animals with congestive heart failure (CHF) and can result in weakness, reduced immunity and survival probability.

The causes of cardiac cachexia syndrome include anorexia, increased energy requirement, and metabolism change. The main cause of cachexia is inflammatory cytokines, such as tumor necrosis factor and interleukin 1, which lead to clinical signs of anorexia, increased energy requirement, and loss of body mass.

Treatment of the symptoms is to **stop the action of cytokines** by using fish oil supplement that contains high level of omega-3 polyunsaturated fatty acids, for example. Fish oil is effective against cachexia and congestive heart failure (CHF), which is the cause of anorexia, therefore it increases appetite of the animals (Freeman, 2013).

High amount of polyunsaturated fatty acid is also found in PCSO-524® (Antinol®), as a result, it improves the condition of cardiac cachexia and increases appetite and body weight.

Treatment of degenerative mitral valve degeneration (DMVD) and cardiac tumor may include **medication to restore normal cardiac function and blood pressure**, and **control of inflammation**. Veterinary care and attention of the owner are necessary since there is a risk for acute complications.

The diagnosis of cardiac tumor using **ultrasonography** to locate the tumor is considered the best diagnostic method in live dogs. Further examination to identify type of the tumor must concern safety of the animals, for example, examination of pericardial fluid is performed in case of pericardial effusion.

References

1. Aupperle H, Marz I, Ellenberger C, Buschatz S, Reischauer A and Schoon HA. Primary and secondary heart tumours in dogs and cats. J comp Pathol .2007;136(1):18-26.

2. Billman G., Kang J. and Lea A. Prevention of Sudden Cardiac Death by Dietary Pure ω-3 Polyunsaturated Fatty Acids in Dogs.Circulation. 1999;99:2452–2457

3. Coulson S, Palacios T and Vitetta L. Perna Caniculus (Green-lipped mussel): Bioactive components and therapeutic evaluation for chronic health conditions. Progress in drug research. 2015; 70: 91-132.

4. Cunningham S. and Hall D. 2011. Heart Failure. The Merck Veterinary Manual:12-13.

5. Freeman L. Nutritional management of cardiac disease. World Small Animal Veterinary Association World Congress Proceedings. 2013

6. Jamikorn U. and Yibchok-auunS. 2014. Effects of dietary polyunsaturated fatty acids supplement in healthy beagle dogs. The Thai Journal of Veterinary Medicine. 44(4): 505-512.

7. Oyama A. An Everyday Approach to Canine Degenerative Mitral Valve Disease. Today's Veterinary Practice. 2012.

8. Rajagopalan V, Jesty S.A., Craig L.E., and Gompf R. Comparison of Presumptive Echocardiographic and Definitive Diagnoses of Cardiac Tumors in Dogs. J Vet Intern Med 2013;27:1092–1096.

9. Ramírez VL, Berrío A, Arias MP. Correlation between the clinical stage, echocardiographic findings and systemic blood pressure in dogs with Degenerative Disease of the Mitral Valve. Rev. CES Med. Zootec. 2016; Vol 11 (2): 61-72.

10. S c h w a rtz D. This Dog Has Ventricular Arrhythmias--What Do I Do?

11. World Small Animal Veterinary Association World Congress Proceedings, 2009

12. Suh S., Han D., Lee S., Hung Y., Choi R. and Hyun C. Chronic Mitral Valve Insufficiency in Dogs: Recent Advances in Diagnosis and Treatment. Open access peer-reviewed chapter. 2016.

13. Treggiari E, Pedro B, Dukes-McEwan J, Gelzer AR, Blackwood L. A descriptive review of cardiac tumours in dogs and cats. Vet Comp Oncol. 2017 Jun;15(2):273-288.

Antinol® (PCSO-524®)
Case Study Contest 2020

Antinol® (PCSO-524®)

Case Study Contest

2020

“

We at **Pharmalink** and **VetzPetz®** have a passion for sciences and a love of our companion animal friends.

Every year we find a new way to help heal our companion animals and each year the vets provide us with the inspiration to dig deeper into our scientific budget to provide essential tools that ultimately will assist the vets, our companion animals, and the pet parents to get the best out of each and every life.

Kevin Cook
President of Vetz Petz® Group

John Waitzer
Pharmalink Director

Nathan Mclean
Pharmalink Director

Please visit **www.Antinolstudies.com** to view more complete studies with over 12 peer reviewed journals and 26 case studies from all Antinol® Contests since 2016

Developed by Science

PCSO-524® efficacy is supported by several veterinary published journals and case studies.

PCSO-524® Contains over 90 stabilized Essential Fatty Acid Fractions including **Omega-3, ETA, OTA, EPA, and DHA**

100% Natural Marine Lipids extract.

The active ingredient is processed without heat and stabilized prior to extraction.

The process protect the therapeutic value of the oil using the patented **CO2 Super-critical extraction** at low temperatures.

The premium lipid extraction process is developed by Pharmalink International. PCSO-524® is then encapsulated with added Natural Olive Oil to increase bioavailability and maintains the oils stability for a period of 3 years.

A natural pure product.
No heavy metals and salt-free.
All contaminants are removed during extraction including heavy metals like Cadmium, and any toxins or pesticides.

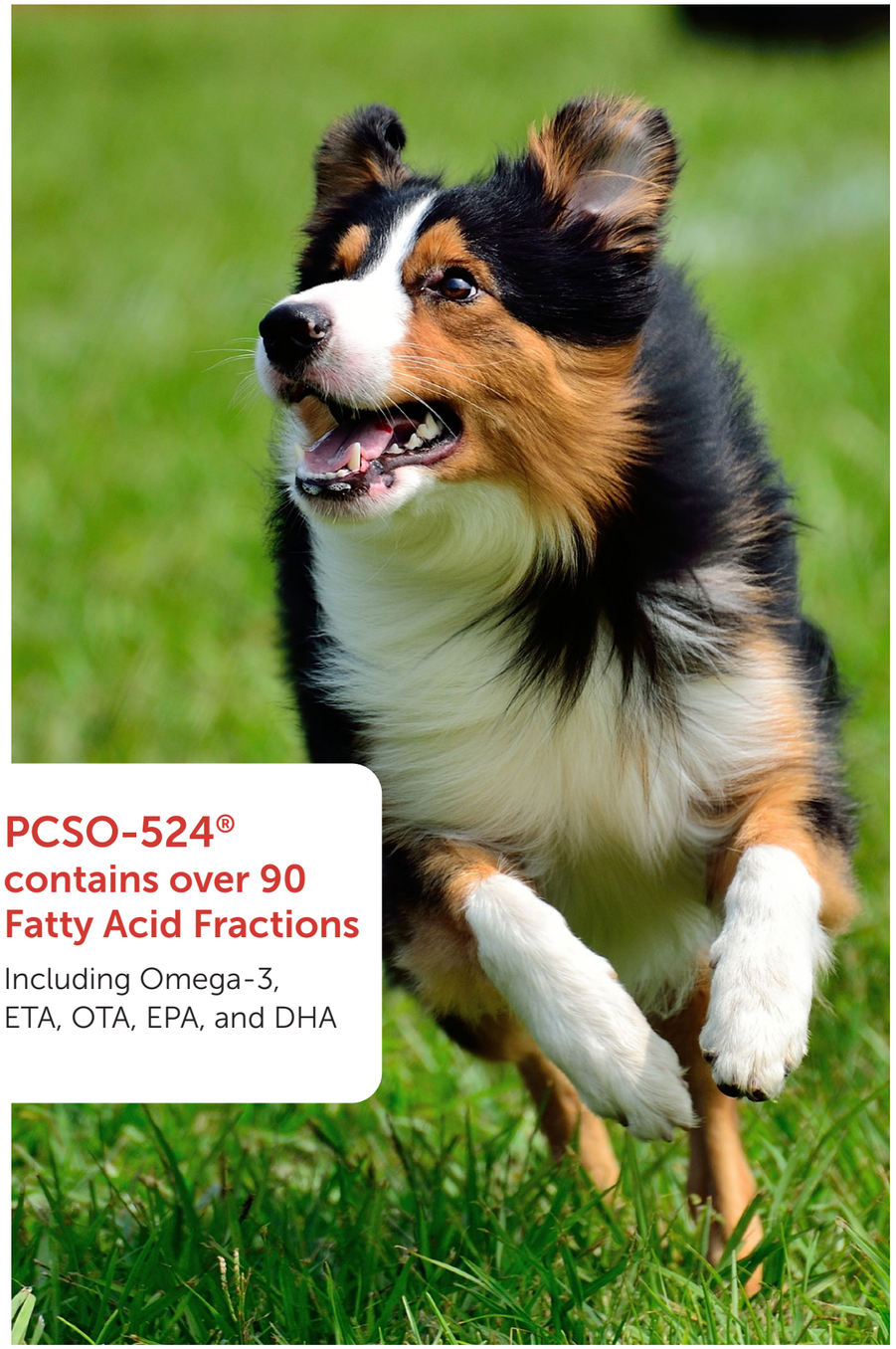

PCSO-524® contains over 90 Fatty Acid Fractions

Including Omega-3, ETA, OTA, EPA, and DHA

GOOD DAYS start with Antinol®

Vetz Petz
Antinol

www.VetzPetz.com

DKSH

Vetz Petz
Antinol

Antinol® PCSO-524® Case Study Contest 2020

Antinol® Case Study Contest 2020

Please scan QR CODE to read more case studies at www.Antinolstudies.com